

Bladder Dysplasia due to Pioglitazone Use

Baweja Himanshu*

*Head of Clinical Pharmacology Dept.,
Medanta-The Medicity, Gurgaon

Gupta Narmada Prasad

Chairman of Urology Dept.,
Medanta-The Medicity, Gurgaon

Introduction

Pioglitazone is a peroxisome proliferator-activated receptor (PPAR) γ agonist used as an adjunct in the treatment of type 2 diabetes mellitus. PPAR γ ligands are known to play a role in altering cell proliferation and differentiation in human bladder cancer cell lines [1, 2, 3]. Recent data has reported a possible linkage between pioglitazone and bladder tumor [4, 5, 6]. This association was first reported in the U.S. pioglitazone label in 1999. Various authors have described the increasing risk of bladder cancer with continued use of pioglitazone for a period of 24 months and above but lack conclusive evidence [4,5]. We report and discuss a patient on pioglitazone therapy presenting with hematuria with bladder dysplasia on biopsy findings.

Case History

A 64 year old male with a history of type 2 diabetes mellitus and hypertension for the past 10 years presented to the urology department with complaints of two episodes of hematuria with passing of clots six weeks back. Smoking history was negative. He was taking tablet pioglitazone 30mgs once daily for a period of 1 year till current visit. General and systemic examination was normal. Hematological and biochemical investigations were normal. CT urography showed mild urinary bladder wall thickening and irregularity along the base and posterior wall. Urine cytology reported superficial squamous cells with occasional lymphocytes. Malignant cells on urine cytology were absent. Cystoscopy revealed normal urethra and bilateral ureteric orifices with elevated bladder neck and velvety red tissue over trigone area. Transurethral cold cup biopsies were obtained from trigone area followed by resection of bladder lesion. Patient was then discharged with the advice of discontinuing pioglitazone and was started on sitagliptin 100 mgs once daily and metformin 1 gm once daily.

Biopsy report revealed urothelial dysplasia [FIG. 1, FIG. 2]. Check cystoscopy was done at 3 months follow up. Cystoscopy showed a well healed area over trigone and velvety edematous lesion above right ureteric orifice. Fulguration of bladder lesion was done and patient was kept on a 6 month follow up. Sitagliptin and metformin were continued. On 1 year follow up patient was clinically asymptomatic with ultrasound kidney urinary bladder region reporting no abnormal findings.

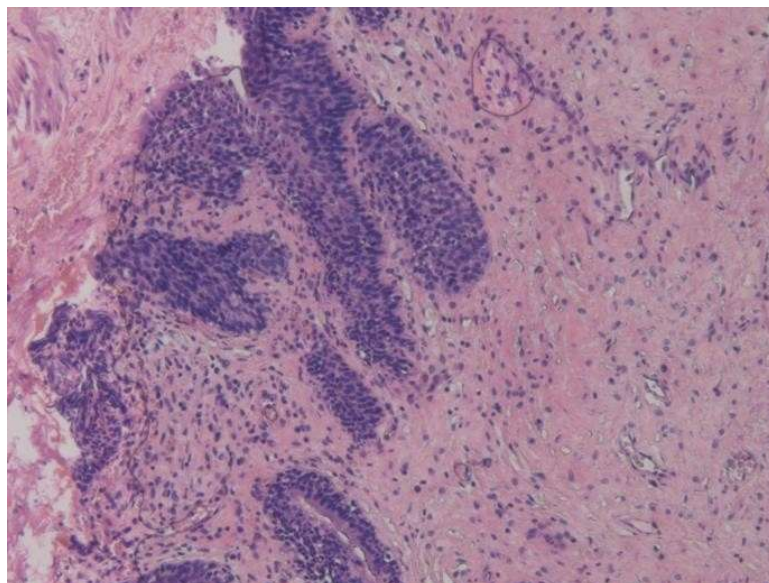


Fig 1:

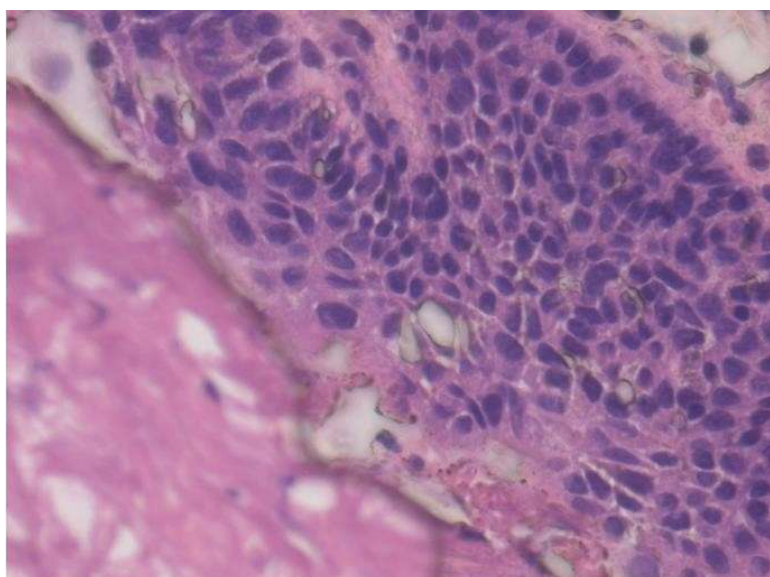


Fig 2:

Discussion

Normal uroepithelial tissue has shown evidence of presence of peroxisome proliferator-activated receptor (PPAR) γ activity and has been detected in bladder tumors [1, 2, 3]. Pioglitazone, an anti-diabetic medication of thiazolidinedione group, is a PPAR γ agonist which is known to cause altered proliferation and differentiation in urothelial tissues. It is associated with an increased risk of bladder cancer possibly attributable to the PPAR γ activity [1, 2, 3]. In a 2 year bioassay, it is reported that pioglitazone induces a relatively low incidence of bladder tumors in male rats. Evidence of this risk in humans has been described in the Prospective Pioglitazone Clinical Trial in Macrovascular Events (PROactive) study. The increased risk of bladder cancer in patients on pioglitazone in this study was, however, concluded statistically insignificant ($P=0.069$) [4, 5]. This study included 2,605 patients as cases (on pioglitazone) and

2,633 as controls (on placebo) with bladder tumor reported in 14 vs. 6 patients in each group respectively. However, exclusion of one patient in the placebo group, as a result of presence of benign histology, the risk proved to be statistically significant (14 vs. 5 cases; relative risk 2.83; 95% confidence interval 1.02 to 7.85) [5, 7]. Majority of bladder cancer cases (8 vs. 3, cases vs. control group respectively) were seen in the first year.

Other studies in the literature also reported a 30% to 40% increase in the risk of bladder cancer on patients treated with pioglitazone for 2 years or more [6,8]. This increase in the incidence of bladder tumors with pioglitazone is associated with an exposure of more than 2 years and a dose of more than 28,000 mg. In one of the studies, 80% of the bladder cancer cases were reported within the first year of starting pioglitazone [8]. In another major study undertaken from the Kaiser Permanente Northern California (KPNC) database reported an incidence rate of 81.5 per 100,000 person years in patients exposed vs. 68.8 per 100,000 person years in patients not exposed to pioglitazone. This study concluded that pioglitazone increases the risk of bladder cancer (adjusted HR 1.22 [95% CI 1.05, 1.43]) [6].

In the present case, the patient had a 1 year history of consuming pioglitazone thereafter showing urothelial dysplasia on biopsy done for hematuria. Confounding risk factors for this disease including cigarette smoking, urinary tract infections, occupational exposure to aromatic amines and polycyclic aromatic hydrocarbons, and exposure to drugs like cyclophosphamide and glucocorticoids, were not seen in the patient.

This case highlights the importance of the association between pioglitazone and bladder epithelial changes. It is important for clinicians to mandate a screening protocol for patients on pioglitazone and stopping the offending drug if dysplastic changes on histology are suspected. This causal association reported between pioglitazone and bladder cancer, with lack of conclusive evidence, warrants additional research in the near future, however, the risks involved necessitates a vigilant approach to similar scenarios.

References

1. Yoshimura R, Matsuyama M, Segawa Y, et al. Expression of peroxisome proliferator activated receptors (PPARs) in human urinary bladder carcinoma and growth inhibition by its agonists. *Int J Cancer* 2003; 104:597– 602
2. Nakashiro KI, Hayashi Y, Kita A, et al. Role of peroxisome proliferator-activated receptor gamma and its ligands in non-neoplastic and neoplastic human urothelial cells. *Am J Pathol* 2001; 159:591–597?
3. Guan YF, Zhang YH, Breyer RM, Davis L, Breyer MD. Expression of peroxisome proliferator-activated receptor gamma (PPARgamma) in human transitional bladder cancer and its role in inducing cell death. *Neoplasia* 1999; 1:330–339
4. Dormandy JA, Charbonnel B, Eckland DJ, et al.; PROactive investigators. Secondary prevention of macrovascular events in patients with type 2 diabetes in the PROactive Study (PROspective pioglitAzone Clinical Trial In macroVascular Events): a randomised controlled trial. *Lancet* 2005; 366:1279–1289
5. Dormandy J, Bhattacharya M, van Troostenburg de Bruyn AR; PROactive investigators. Safety and tolerability of pioglitazone in high-risk patients with type 2 diabetes: an overview of data from PROactive. *Drug Saf* 2009; 32:187–202
6. Lewis JD, Ferrara A, Peng T, Hedderston M, Bilker WB, Quesenberry CP Jr, et al. Risk of bladder cancer among diabetic patients treated with pioglitazone: interim report of a longitudinal cohort study. *Diabetes Care* 2011; 34:916–22.5
7. Hillaire-Buys D, Faillie JL, Montastruc JL. Pioglitazone and bladder cancer. *Lancet* 2011; 378:1543–4.
8. Chin-Hsiao Tseng. Pioglitazone and Bladder Cancer A population-based study of Taiwanese. *Diabetes Care* 2012; 35:278–280.